

East African Medical Journal Vol. 83 No. 7 July 2006

HEMIFACIAL SPASM: CASE REPORT

J.O. Jowi, MBChB, MMed, Dip. Clin Neurol (Queen Square London), Consultant Neurologist and Chief Medical Specialist, Kenyatta National Hospital, P.O. Box 19624-00202, Nairobi, Kenya, J. Matende, MD, Consultant Ophthalmologist, Lighthouse for Christ Eye Centre, P.O. Box 81465, Mombasa, Kenya and M.I. Macharia, MBChB, MMed (ENT) Associate Professor, Department of Surgery, College of Health Sciences, University of Nairobi, P.O. Box 29740, Nairobi, Kenya

Request for reprints to: Dr. J.O. Jowi, P.O. Box 19624-00202, Nairobi, Kenya

HEMIFACIAL SPASM: CASE REPORT

J.O. JOWI, J. MATENDE and M.I. MACHARIA

SUMMARY

A 53 year old lady with diabetes mellitus presented with right hemi-facial spasm (HFS). Brain MRI Scan revealed extensive pan-sinusitis and mild bilateral mastoiditis. She responded well to intravenous ceftriaxone therapy and the hemifacial spasm resolved. The symptoms of hemifacial spasm and pain over the right cheek and peri-orbital area recurred after three weeks. She was admitted to hospital for Functional Endoscopic Sinus Surgery (FESS); following findings on repeat para-nasal sinus CT-Scan. Several reviews over six month's period revealed complete resolution of hemi facial spasm symptoms save for mild intermittent right blepharospasm; particularly on exposure to wind. This is a very rare cause of hemifacial spasm and clinicians should be on the look out for infective/inflammatory aetiology of hemifacial spasm; particularly in patients who present with recent onset HFS and have features of infection and or inflammation in the cranium.

INTRODUCTION

Hemifacial spasm (HFS) is a movement disorder characterised by unilateral paroxysmal involuntary contractions of the facial muscles. It was first described by Gowers in 1884. Bilateral hemi-facial spasm is very rare (1). Common causes include vascular loop compression at the root exit zone of the facial nerve (2). The offending vascular loop may be the distal vertebral artery, basilar artery or the smaller vessels such as anterior inferior cerebellar artery or posterior inferior cerebellar artery (3). Other causes include arterio-venous malformations, parotid gland tumour, Pagets disease, cerebello-pontine angle meningioma, acoustic schwannoma; all being compressive lesions. Non-compressive causes include multiple sclerosis, diabetic ketoacidosis, stroke, basilar meningitis, marfan's syndrome. Familial cases have been reported. A majority of cases of HFS are idiopathic (4-11).

Literature search in Pub Med; Search words being 'Causes of Facial Spasm' revealed enormous data (631 papers) from 1950 to March 2006. Only one paper (12) indicates a case report of otitis media with effusion (an infective aetiology) causing facial spasms.

The case reported herein is therefore unique and is probably one of the very few documented cases in world literature of pan-sinusitis (an infective aetiology) causing hemi-facial spasm.

CASE REPORT

A 53 year old lady was referred for evaluation of right hemi-facial spasm by her ophthalmologist.

She gave a history of progressive worsening right facial muscles involuntary movements which started five months prior to the referral. It was associated with periorbital and facial bone pains on the same side.

She had been diagnosed to have Type 2 diabetes mellitus in the year 2000 and her blood sugar was well controlled. Her ophthalmologist did not find any significant features of diabetic eye disease. She had no other significant past medical history.

Physical examination revealed a middle aged lady in good general condition. She was normotensive and had no fever. She was fully conscious and alert.

She had normal cognition, there was no cranial nerve palsy; facial sensation was normal. She had right hemi-facial spasm beginning with orbicularis oculi with downward spread to all other facial muscles. There was tenderness of the right facial bones especially the zygomatic arch. Other neurological examination was normal. No significant findings were noted on clinical examination of the other systems.

Various investigations were done, full blood count, HbA1c, Fasting Lipid Profile; the results of which were unremarkable. Brain MRI scans with gadolinium enhancement was done (Figure 1); it

indicated extensive pan sinusitis with bilateral mastoiditis. The VIIth and VIIIth cranial nerve complexes were normal bilaterally. Brain examination was normal. She was commenced on intravenous ceftriaxone and non-steroidal anti-inflammatory medication and review ten days later revealed complete cessation of the hemi-facial spasm and tenderness of facial bones. She was referred back to the ophthalmologist. She presented again three weeks later with recurrence of symptoms of right hemi-facial spasm and right facial bones pain and tenderness. She was re-started on oral antibiotics for two weeks with poor response i.e. facial spasm and facial bone pains persisted. Para nasal sinus CT-Scan was then done, (Figure 2), it still showed features consistent with pan sinusitis and mild mastoiditis. She was admitted to hospital for (FESS) by the otolaryngology surgeon. Review, six months later post surgery, reveals no recurrence of symptoms. She had no hemi-facial spasm save for mild intermittent right blepharospasm on exposure to wind.

Figure 1

Brain MRI scan of a 55 year old female with hemifacial spasm. It shows normal V11 and V111 cranial nerve complexes bilaterally; pan sinusitis and mastoiditis

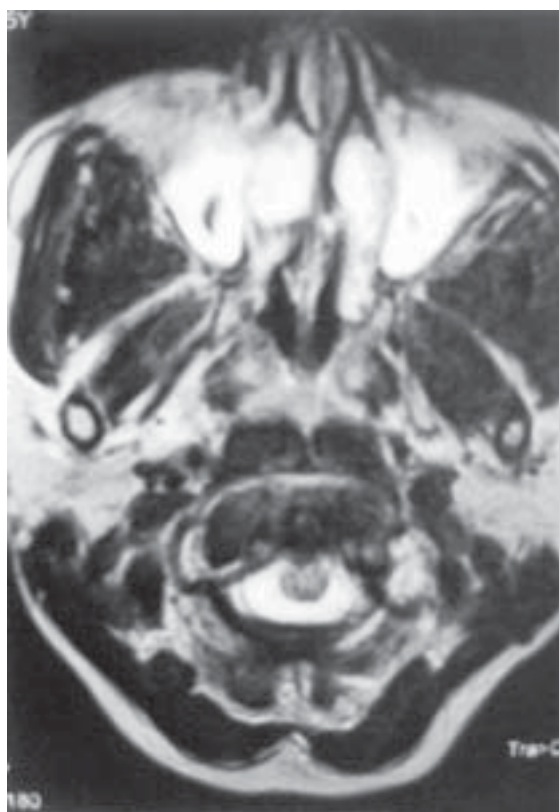
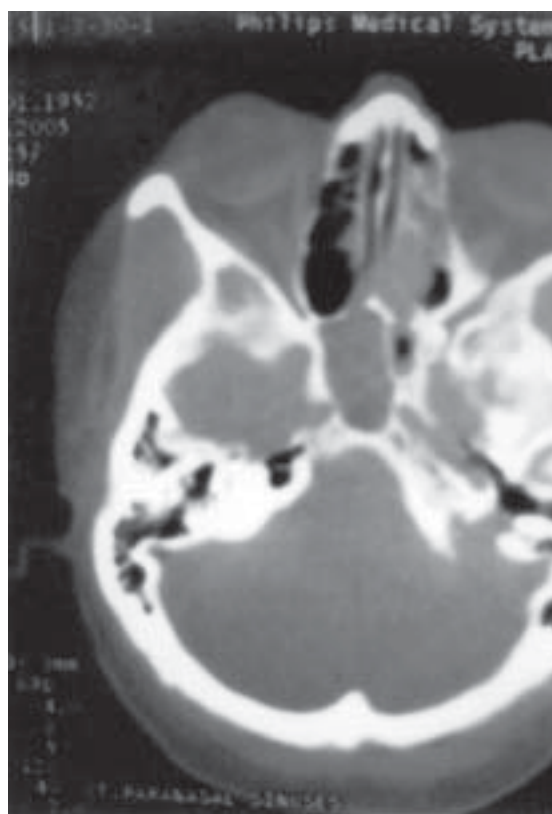


Figure 2

Para nasal sinus CT-scan of a 55 year old female with hemifacial spasm. It shows osteomeatal and sphenoidal patterns of pan sinusitis



DISCUSSION

Hemi facial Spasm (HFS) is rare. The VIIth cranial nerve makes us individuals; the facial expression of each individual is determined by its functions. The nerve is commonly divided into four segments for examination i.e. the nucleus and tracts; the cisternal segment that traverses the internal auditory canal; the intra-temporal segment (through the bony facial nerve canal) and the peripheral segment (3).

Pathology can involve the nerve anywhere along its course. The most common cause of HFS is compressive, ecstatic blood vessel at the root exit zone. Only one documented case of Otitis media with effusion in a six-year-old girl was found. This girl's symptoms promptly resolved after insertion of ventilator tubes in the course of her otolaryngology management (12).

The case herein presents a rare situation of pan sinusitis causing hemi facial spasm.

The pathophysiology of hemi facial spasm in this patient is not clear. However, the probable explanations would include inflammatory processes causing irritation of the facial nerve as it traverses the intratemporal and/or cisternal segments of its pathway (3). It is therefore important for clinicians to think of an infective/inflammatory aetiology for HFS in patients presenting with recent onset HFS and features of infection and/or inflammation as in this lady. She had tenderness of facial bones ipsilateral to the hemi facial spasm indicating inflammation. Diagnosis was suggested by imaging and she responded to antibiotic treatment. Her diabetes mellitus probably predisposed her to fulminant infection. Diabetic ketoacidosis can cause hemi facial spasm (10); however, this was not the case in this patient as she had good glycaemic control throughout her management.

The imaging of choice in evaluating disorders of the facial nerve along its pathway is Magnetic Resonance imaging Scan. This patient had fulminant features of inflammation, the MRI scan excluded VIIth cranial nerve root complex compressive lesions.

In cases where no apparent aetiology for HFS is ascertained or the cause is due to some inoperable compressive lesions; Botulinum toxin therapy is the

mode of choice of management for symptomatic relief of the facial spasm.

The definitive management of HFS depends on the cause. Vascular compressive lesions are managed by surgical decompression. Other modes of management include use of baclofen and carbamazepine or gabapentin.

In conclusion, hemifacial spasm is often an embarrassing disorder. The commoner causes are often not amenable to ready treatment and require very skilled surgical decompression or expensive remedies like Botulinum toxin injection. Clinicians should be on the lookout for treatable causes such as infection and/or inflammation. This patient and the one recorded (12) are examples.

ACKNOWLEDGEMENT

To Kenyatta National Hospital Ethics and Research Committee for permitting the publication of this case report.

REFERENCES

1. Tan E.K. and Jankovic J. Bilateral hemi facial spasm: a report of five cases and a literature review. *Mov. Disord.* 1999; **14**: 345-349.
2. Wilkins R.H. Hemi facial spasm: a review. *Surg. Neurol.* 1991; **36**: 251-277.
3. Philips C.D. and Bubash L.A. The facial nerve: anatomy and common pathology. *Semin. Ultrasound CTMR.* 2002; **23**: 202-217.
4. Braca J., Hornyak M. and Murali R. Hemi facial spasm in a patient with Marfan syndrome and Chiari I malformation: Case report. *J. Neurosurg.* 2005; **1003**: 552-554.
5. Galvez-Jimenez N., Hanson M.R. and Desai M. Unusual causes of hemi facial spasm. *Semin. Neurol.* 2001; **21**: 75-83.
6. Adler C.H., Zimmerman R.A., Savino P.J., *et al.* Hemi facial spasm: evaluation by magnetic resonance imaging and magnetic resonance tomographic angiography. *Ann. Neurol.* 1992; **32**: 502-506.
7. Jannetta P.J., Abbasy M., Maroon J.E. *et al.* Etiology and definitive microsurgical treatment of hemi facial spasm. Operative techniques and results in 47 patients. *J. Neurosurg.* 1977; **47**: 321-328.

8. Moller A.R. The cranial nerve vascular compression syndrome I. A review of treatment. *Acta. Neurochir (Wien)*. 1991; **113**: 18-23.
9. Moller A.R. The cranial nerve compression syndrome II. A review of pathophysiology. *Acta. Neurochir (Wien)*. 1991; **113**: 24-30.
10. Bandyopadhyay S.K. and Dutta A. Hemifacial spasm complicating diabetic ketoacidosis. *J. Assoc. Physicians India*. 2005; **53**: 649-650.
11. Micheli F., Scorticati M.C., Gatto E., *et al.* Familial hemifacial spasm. *Mov. Disord*. 1994; **9**: 330-332.
12. Lavon H., Cohen-Kere R. and Uri N. Hemifacial spasm associated with otitis media with effusion: A first reported case. *Int. J. Paediatr. Otorhinolaryngol*. 2005 Nov 14; (Epub ahead of print).